

PUBLISHED BY

# INTECH

open science | open minds

World's largest Science,  
Technology & Medicine  
Open Access book publisher



**2,950+**  
OPEN ACCESS BOOKS



**100,000+**  
INTERNATIONAL  
AUTHORS AND EDITORS



**96+ MILLION**  
DOWNLOADS



**BOOKS**  
DELIVERED TO  
151 COUNTRIES

AUTHORS AMONG  
**TOP 1%**  
MOST CITED SCIENTIST



**12.2%**  
AUTHORS AND EDITORS  
FROM TOP 500 UNIVERSITIES



Selection of our books indexed in the  
Book Citation Index in Web of Science™  
Core Collection (BKCI)

Chapter from the book *Hair and Scalp Disorders*

Downloaded from: <http://www.intechopen.com/books/hair-and-scalp-disorders>

Interested in publishing with InTechOpen?  
Contact us at [book.department@intechopen.com](mailto:book.department@intechopen.com)

---

# The Histological Mechanisms of Hair Loss

---

Vsevolodov Eduard Borisovich

Additional information is available at the end of the chapter

<http://dx.doi.org/10.5772/67275>

---

## Abstract

The growing hair resists pulling out of the skin in particular site, where the keratinization of hair cortex and hair cuticle cells as well as the cells of the hair inner root sheath (IS) (being in tight contact) are advanced enough to make them rather strong but lower the level where the hair separates from the hair inner root sheath. The hair which does not grow is kept for some time within the skin by the direct contact of the keratinized hair cortex cells with the cells of the hair outer root sheath. Such contact is absent at the phase of growing hair and even in the case of proliferation inhibition in the follicle bulb causing the lack of hair resistance to pulling it out of the skin several days after inhibition induction.

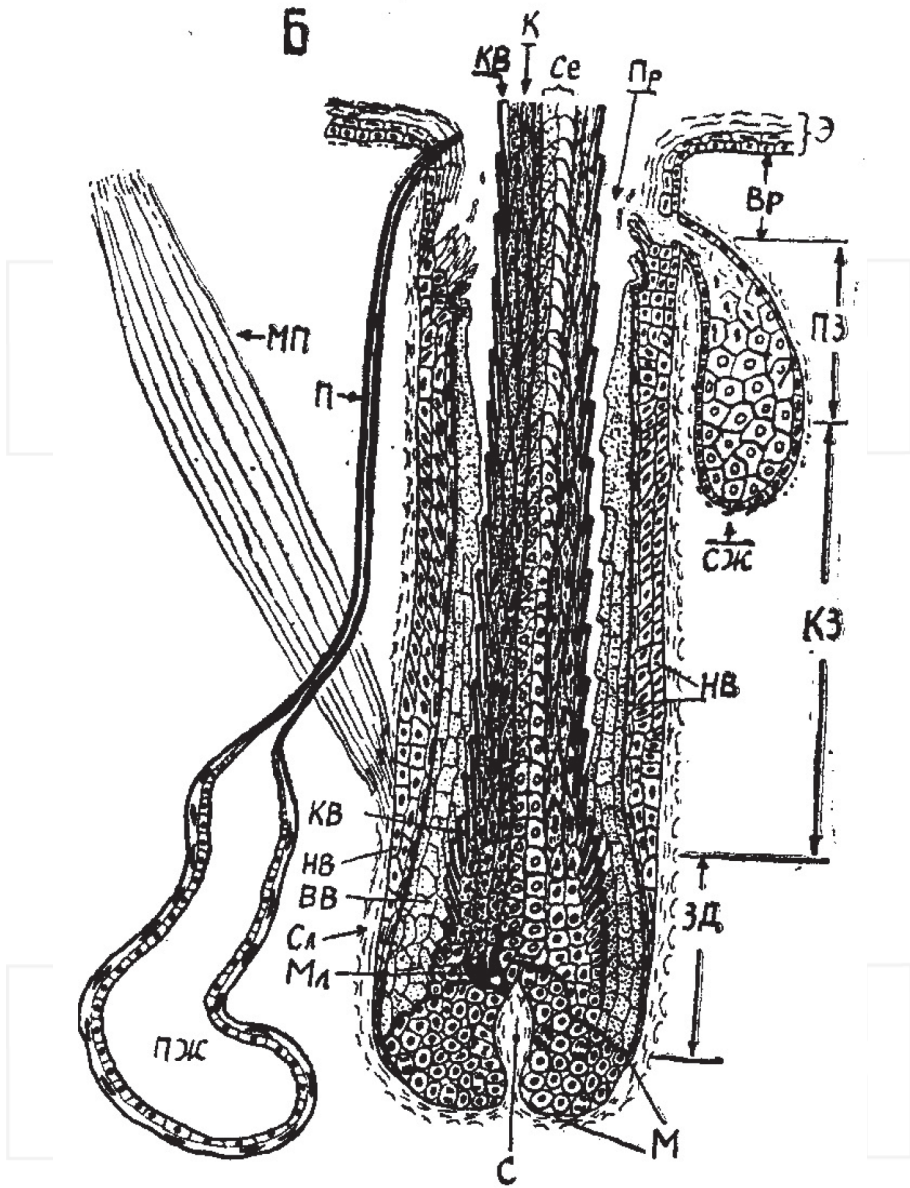
**Keywords:** hair matrix dysplasia, hair break, hair upward promotion, cell proliferation/evacuation balance

---

## 1. Introduction

First of all let us remember most briefly the histological structure of the hair follicle (F) (**Figure 1**) in the phase of stable hair growth [1–3]. The lowest (innermost) part of the hair F is presented by hair bulb including its cambium zone (“matrix”), which consists of cells dividing all the time while the hair grows. These cells do not seem to differ from each other. Their division does not cause the increase of the matrix volume while hair growth is stable because the number of newly produced cells equals the number of the cells leaving matrix and starting to differentiate into the layers of the hair (medulla, cortex, and hair cuticle) and hair root inner sheath (inner sheath cuticle, Huxley layer, and Henle layer). All six layers move upward (toward the skin surface). In the course of differentiation, the cells of all these layers stop dividing and start to synthesize several types of keratins (K) or “keratin-like” (KI) proteins [2]. The sets of these proteins are different in the medulla, cortex, and cuticle of the

---

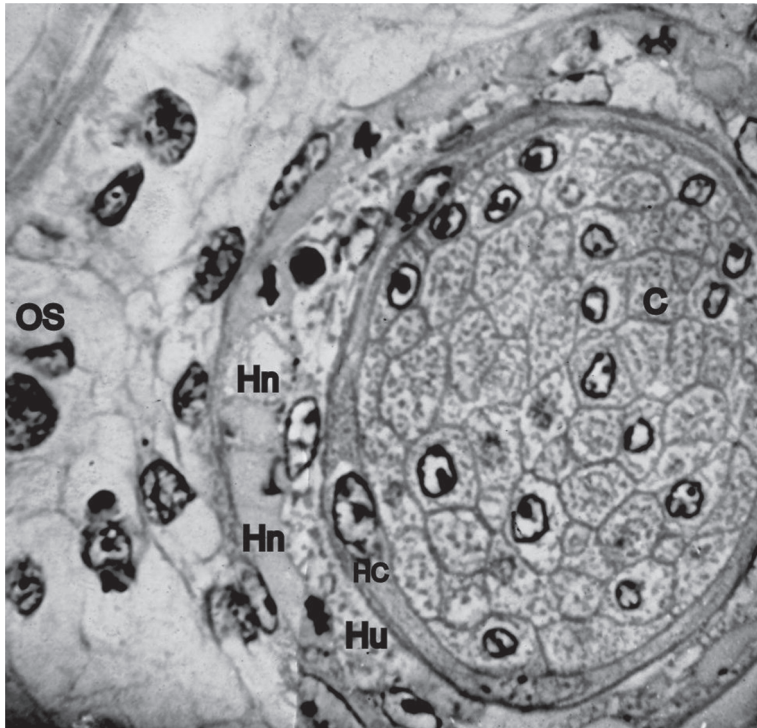


**Figure 1.** General scheme of the hair follicle in the phase of stable hair growth. M, matrix (cambium zone); C, connective tissue papilla; ЗД, zone of differentiation; КЗ, zone of keratinization; ПЗ, postkeratogenic zone; Вр, hair follicle infundibulum; Э, interfollicular epidermis; СЖ, sebaceous gland; ПЖ, sweat gland; Ce, hair medulla; K, hair cortex; KB, hair cuticle; ВВ, hair inner root sheath; НВ, hair outer root sheath; СА, connective tissue sheath around the hair follicle ("vitreous membrane"); and Мл, melanocyte (melanin-producing cell). МП, musculus arrector pili; П, sweat gland duct; and Пр, the pilary lumen (the fissure separating hair from inner root sheath by the end of differentiation).

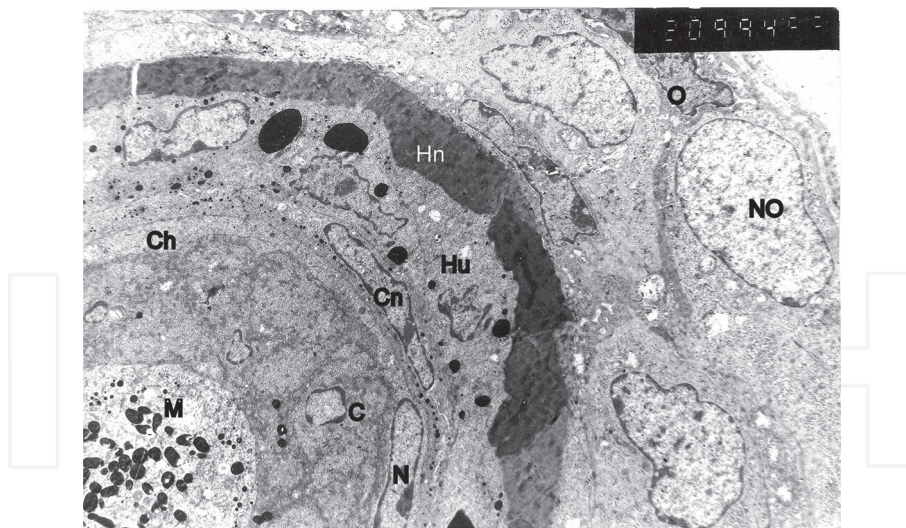
hair. The morphological features of these layers are also very different. The main hair layer is the cortex. Its cells have spindle-like form with their long axes parallel to hair length. Almost all cell volume is filled with K fibers when the K synthesis is over. The neighboring cortex cells are agglutinated by the strong intercellular glue capable to resist the water.

The outermost hair layer—the cuticle—has no fiber structures. The cell has the somewhat curved plate-like form as the cell “tries” to surround the hair (Figure 2). The upper ends of the hair cuticle cells lie over the lower parts of the preceding (more distal) cuticle cells of the hair so that the general pattern resembles the piling (Figure 3). So the upper ends of cuticle cells stick out of the hair surface like the dents of gear wheel. This pattern is imprinted on the inner root sheath (IS) cuticle surface, and the dents of the hair cuticle are inserted between the corresponding dents of IS cuticle like the dents of a joint gear wheel pair (Figures 4 and 5).

Hair cortex and cuticle K contain some sulfur-rich proteins preventing K destruction by proteases because the sulfur-containing amino acids bind molecules of K with each other or the



**Figure 2.** A transversal section of fine-wool sheep hair follicle (no medullar layer is present). C, the cell of cortex layer. The visible cell borders are “underlined” by keratin layer on the inner side of cytomembranes as well as in central parts of the cytoplasm. The nuclei are present only in the cells which were cut across in the middle part of spindle-like cell where the nucleus is located. HC, hair cuticle. This plate-like cell “tries” to surround the hair root. Hn and Hu, Henle and Huxley layers of inner hair root sheath. OS, hair outer root sheath. Hematoxylin + eosin.



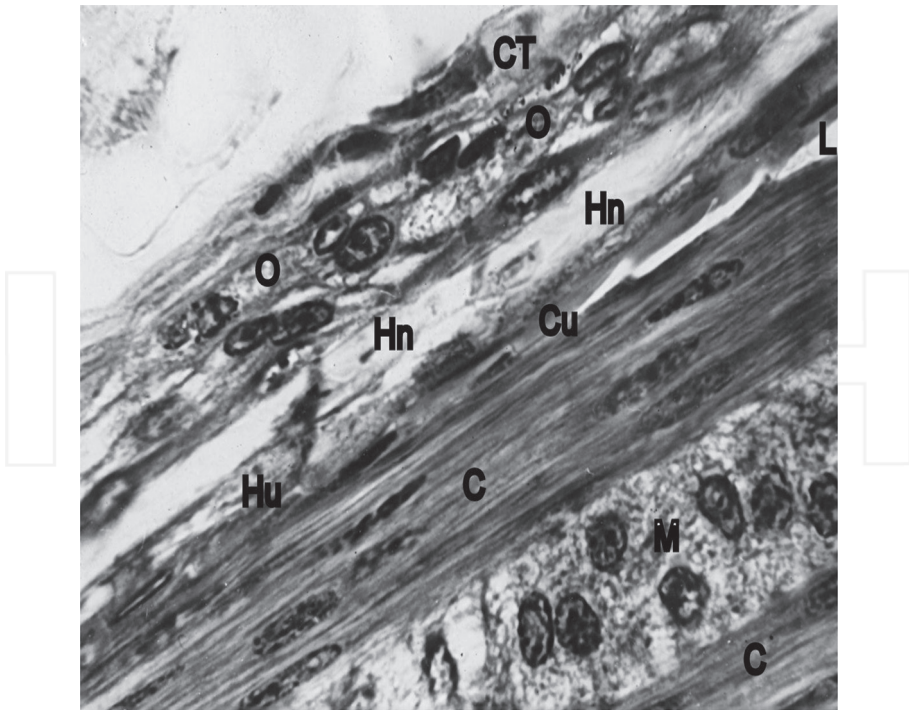
**Figure 3.** The electron microscopic photo of the transversal section of mouse hair follicle on the level of keratogenic zone. M, hair medulla containing larger black particles corresponding to melanosomes (diameters about 0.5  $\mu\text{m}$ ) and with much less diameters (trichohyalin-like material). C, hair cortex. N, nucleus of the hair cuticle—very flat cells of the hair outer layer lacking trichohyalin. Cn, the nucleus of the inner hair root sheath cuticle including little black particles of the trichohyalin. Both cuticles are lying close to each other fixing the hair within the hair follicle. Hu, middle layer of the inner sheath, including some very large black trichohyalin granules. He, outer layer of the inner sheath which unlike Huxley layer is already keratinized. NO, the nucleus of nonmigrating cell of the outer layer of outer hair root sheath. O, the cell of the same layer but starting migration toward Henle layer, forming long pseudopodium for this purpose.

parts within the same molecules by many disulfide “bridges” (–S–S–) which do not allow large protease molecules to reach the proper sites of K molecules to hydrolyze them.

The most obvious feature of the hair medulla cells is rather poor keratinization (**Figures 3 and 4**). When this process is over, very high proportion of the cell volume is filled by the air. So the cells seem to be “half empty.” Some KI material usually is present under the cell membrane, and some other KI materials cross the cell as rather rare fibers (in sheep hair), but we must take into account that medulla cells’ morphology is extremely polymorphic when we compare different taxons.

The KI material of the inner root sheath (IS) does not contain much sulfur and is partly hydrolyzed by proteases in the upper segment of the F. The chemical nature of the KI material in all three layers of the IS does not seem to differ much. But morphologically they can be easily distinguished in the lower part of the follicle thanks to heterochrony of their keratinization process. In the outer layer (Henle) of the IS, the synthesis of KI material begins earlier (lower) than in other F layers, progresses faster, and becomes the first solid structure on the way from the F bottom to the skin surface (**Figures 3 and 4**). The same phases of KI material synthesis take place later (on the higher level of the F) in IS cuticle and especially in the middle (Huxley) layer.



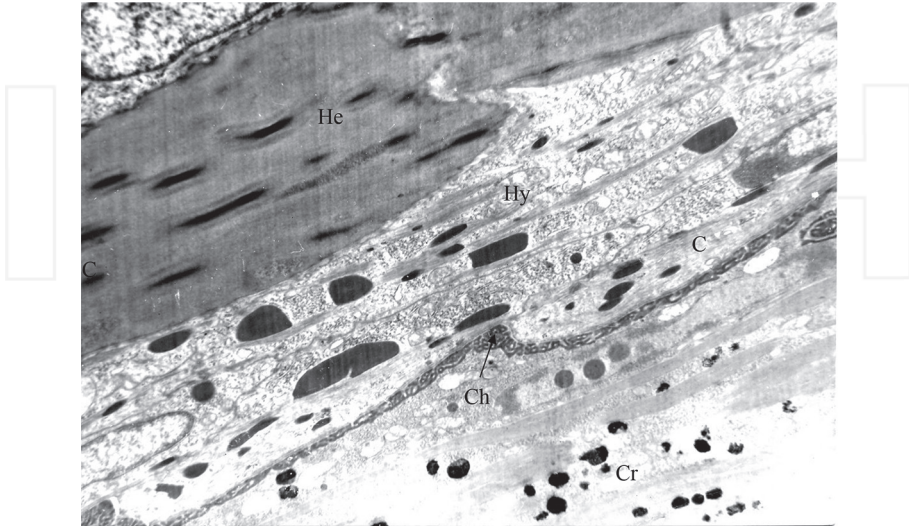


**Figure 4.** Longitudinal section of a sheep hair follicle on the level close to the end of keratogenesis. C, hair cortex; M, medulla; Hn, Henle and Huxley layers; O, outer root sheath; and CT, connecting tissue surrounding the hair follicle. Cu, two cuticles (hair cuticle and inner root sheath cuticle) starting to separate by pilary lumen —L— (right half of the photo) and tightly bind lower (left half of the photo where no lumen is present). Slightly projecting out of hair surface “dents” of upper hair cuticle edges that are imprinted in inner root sheath cuticle cells. So these dents of the hair cuticle are inserted into indentations of inner root sheath cuticle like the dents of a gear wheel into indentations of another gear wheel.

The hair outer root sheath (OS) surrounds the IS and even matrix. Its cells do not originate from the matrix, and at least outer layer cells of the OS do not move upward like the cells of the hair and IS [4]. Outer layer cells of the OS can move downward toward the bottom of the matrix, penetrate into it, and renew its proliferation potential after its decrease after some damages or as Hayflick limit [5] being exhausted. OS outer layer contains stem cells of the hair F, and its cambium cells are located in the OS outer layer over the hair F bulb. The cells produced by this cambium zone migrate from the outer layer of OS into the inner (“companion”) layer which, unlike cells of the OS outer layer cells, move permanently upward together with IS and hair cells [6].

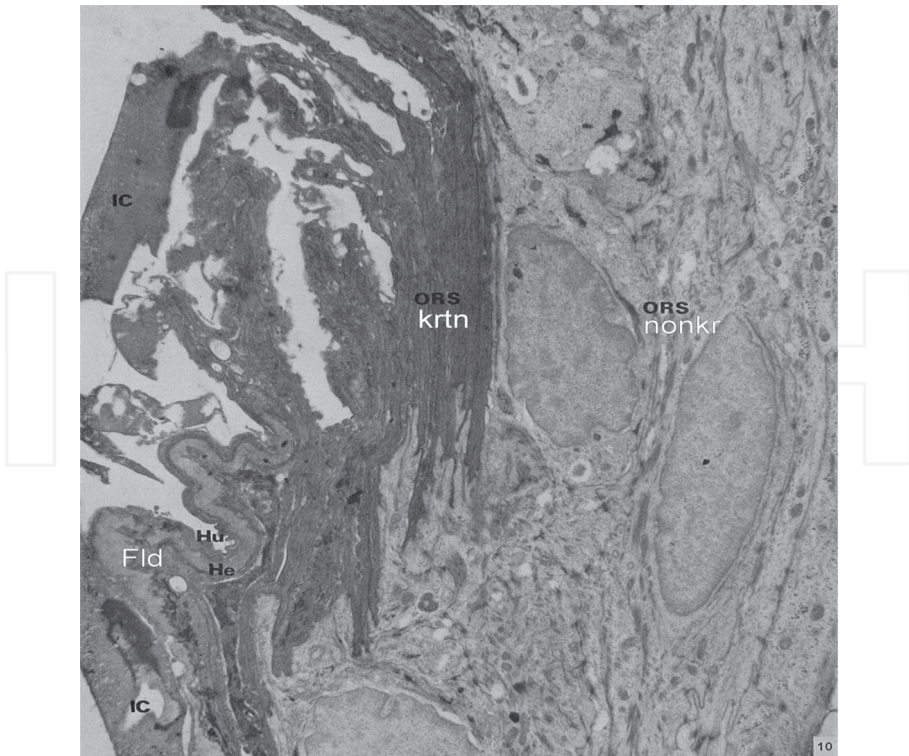
The structure of the OS is very different depending upon the F level (from matrix bottom to the skin surface). On the deepest level around the matrix, the outer and inner cell layers are presented each by the single row of very flattened cells having the thickness less than 1 mcm except the sites close to the nuclei of the cells. Over the bulb the OS becomes much thicker than around the matrix and consists of three and more rows of cells which are not

flat but cubic or cylindrical (except the inner OS layer cells which are rather flat). Some of the outer layer cells proliferate and display the inward amoeboid movement toward IS wedging between the already present companion cells arrived from below. Then these cells become new elements of companion layer and take part in its upward movement together with the IS and hair [4, 7].



**Figure 5.** Electron microscopic photo of the part of longitudinal section of the keratinization zone sheep hair follicle on the border of the hair and hair inner root sheath. The hair growth direction is from low left to upper right. Cr, cortex of the hair with melanosomes. Ch, cuticle of the hair. The long apoptotic nucleus of the hair cuticle cell is just to the right from Ch letters. Arrow, “labyrinth-like” epicuticular layer of the immature hair cuticle. C, hair root inner sheath cuticle cell with trichohyalin black granules. Its lower end protrudes into the hair, and the hair cuticle protrudes below it to the inner sheath arranging gear wheel-like indentations. Hy, Huxley layer with large black trichohyalin granules. He, keratinized Henle layer folded in the course of cutting.

The uppermost portion of the OS—the hair F infundibulum—has the same structure as the interfollicular epidermis of the skin surface. It produces the keratinized squamous cells and lays them around the fully differentiated hair. Neither IS nor companion layer are present in the infundibulum as no ascending cell flow exists there. So rather quick upward movement of partly hydrolyzed IS and companion layer is stopped running against this obstacle. New and new portions of the IS and companion layer arrive and form folds projecting into the pilary lumen (**Figure 6**). By this moment partly hydrolyzed IS starts to destroy and the companion layer cells finish their keratinization [8]. These keratinized cells do not seem to hydrolyze like the IS. Their K must be of the different nature and can resist enzyme hydrolysis. Keratinized cell processes of the companion layer cells penetrate into nonkeratinized cells of OS middle layer cells (**Figure 6**) which may stabilize the folds for some time, and destruction and exit of arriving from below companion layer cells into the pilary lumen are postponed for some time.



**Figure 6.** Most informative electron microscopic photo of the pattern of the sheep hair follicle wall at the level just under the sebaceous gland orifice made by Gemmel and Chapman [8]. Anagen VI phase of hair growth cycle. Fld, folds are formed by three layers of the hair follicle inner hair root sheath (IC, cuticle; Hu, Huxley; Hn, Henle) and keratinized companion layer of the outer sheath (ORS ktrn). The long keratinized processes of the companion layer are inserted into the nonkeratinized outer sheath cells (ORS nonkr) which seem to retard the desquamation of keratinized companion cells.

The hair F is surrounded by the condensed connective tissue (vitreous membrane) which like peninsula intrudes into the matrix (papilla). The vitreous membrane includes the layers of collagen fibers oriented longitudinally and circularly (around the F). The basal membrane is present on the border of the F epithelium and surrounding connective tissue including the papilla.

We must realize how the hair is normally fixed in the skin while it grows. Once I could see how my assistant caught rather large crossbred ram grasping from behind two portions of wool on both sides of its body holding them in his clenched fists. The ram pulled my assistant forward and the heels of his boots made a deep long furrow in the soil before my assistant could stop the ram.

So hairs are fixed in the skin strongly enough. It does not seem to be easily expected after the preliminary analysis of hair follicle histologic structure. Indeed the keratinized hair upper part consists of rather strong composite material including protein filaments agglutinated by



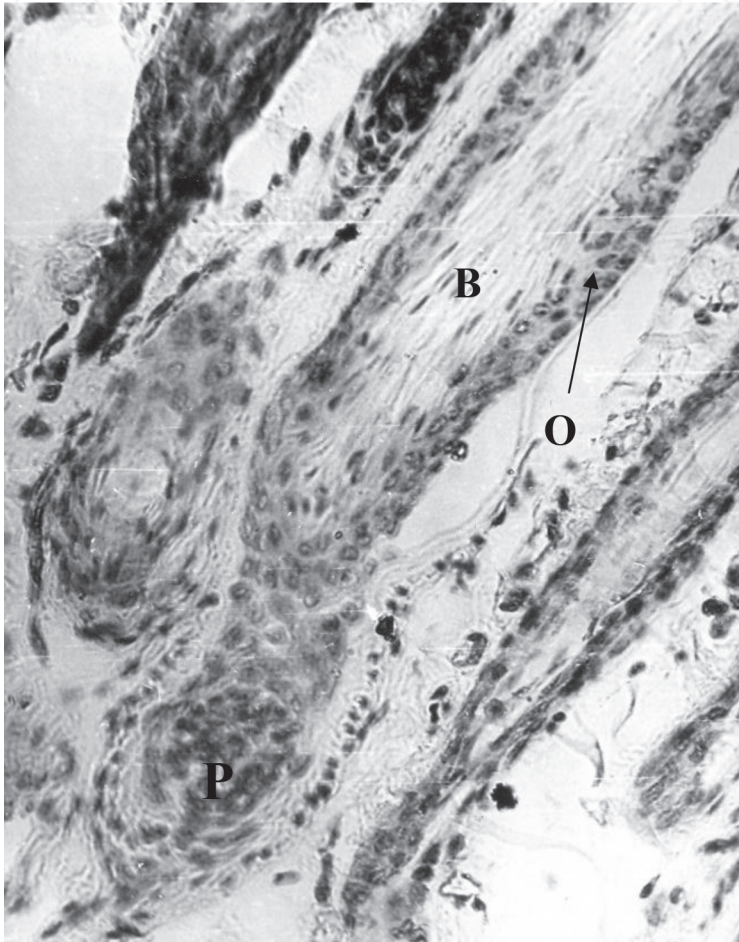
nonfibrous proteins. In the upper part of the F, the hair is separated by the fissure from the surrounding tissue layers which makes it impossible for upper part of the hair to resist pulling out of the skin (**Figure 4**). Following deeper along the less and less “mature” hair, we reach after all the cambium zone (“matrix”) of the F where cells divide providing new and new cell material for hair growth. Permanently dividing cells cannot include hard materials which would make impossible to produce two equal daughter cells. So the lack of hard materials in the matrix means it is practically liquid substance and cannot resist pulling the hair out of the skin. It would be as expecting the water in the vase to resist pulling out a bouquet from a vase. Even immediately over matrix where the cell division stops and hair cortex and hair cuticle keratinization is in the very beginning, hair root does not differ much from the matrix in its capacity to resist pulling out of the skin.

Where the hair is really fixed strongly in the F? This position is over the level of start of keratinization but below the level of hair separation from the surrounding F layers (more exactly from the inner layer of the IS—the cuticle of the IS). As we mention above, the dents of the hair cuticle are inserted between the corresponding dents of IS cuticle like the dents of a joint gear wheel pair. When we try to pull the hair out of the skin, our exertion is transmitted from the mature (fully keratinized) hair to the portion of the hair essentially keratinized, then through the hair cuticle dents to the dents of the IS cuticle, and further to almost fully keratinized IS then to the OS and to some extent to connective tissue vitreous membrane. The exertion of pulling out the hair is supposed to be transferred along the following trajectory: mature (fully keratinized) hair → essentially but not fully keratinized hair → its cuticle dents → the dents of IS dents—almost fully keratinized IS → OS → to some extent to connective tissue vitreous membrane. The pulling exertion will cause upward moving of the hair and outward folding of the IS and OS which will be limited by almost unstretchable vitreous membrane. So the folding will squeeze the hair and will not allow the hair to leave the F easily. So the hair is pulled out only with some portions of IS and OS. The regrowth of the hair in the follicle from which the growing hair was pulled out starts almost immediately. If we change rather careful pulling the hair out of the skin for very abrupt jerking out, then even the bulb with the matrix can be extracted from the skin and no hair regeneration will follow.

So rather strong fixation of the growing hair within the skin seems to be based on the impossibility of hair slipping against the IS caused by interdigitating gear wheel-like dents on the hair and IS surfaces. This obstacle for free sliding exists only on the definite level of the F. As the hair and IS cells move up from this level, the hair separates from the IS, but by this moment, new portions of maturing to proper state hair and IS cells take their place and support growing hair “anchoring” function.

The phase of stable hair growth (anagen VI) is interrupted after some time of hair growth by the phase of no growth (telogen). Depending upon the position on the site of the body surface, species peculiarity, and some other factors, the transition of an F to telogen phase happens after a few weeks of hair growth and up to several years of growth. The daily increase of the hair length in the phase of anagen VI varies usually within the range of 0.3–1.0 mm/day. So the hair length about 1 m (scalp region) of the human can be obtained by the hair growth for approximately 5–6 years, and the hair length about 5 mm (brows) can be obtained by the hair

growth for approximately 2 weeks. The transition from anagen VI to telogen occurs through the phase named the catagen. In the course of it, cell division decreases and stops. The IS is not produced. There appears the hair proximal end looking like the brush with the keratinized cortex most proximal cells sticking out apart and contacting directly with OS companion layer cells as the IS is absent and does not isolate hair cortex from the OS (**Figure 7**). The upward movement of the hair and companion layer goes on even when no proliferation in the disappearing matrix takes place. Its mechanism is based on the active OS cell migration. The upward movement stops below the sebaceous gland orifice. The hair keratinized brush-like end cells keep for some time (several days or months) their tight binding to also keratinized



**Figure 7.** A telogen phase hair follicle of sheep. P, hair follicle papilla ascended upward after the brush-like (B) lower hair end (“club”) which is directly connected with outer hair root sheath (O) unlike anagen phase (growing hair) follicle where the hair is separated from the outer sheath by the inner sheath. Hematoxylin + eosin.

by this moment OS inner layer cells surrounded by the cells of nonkeratinized outer layers of the OS. In such a way, the nongrowing hair is anchored in the skin. Its loss from the skin is postponed after stopping the growth up to the moment when the keratinized companion layer cells will be peeled into the pilary lumen, and the hair will be shed out of the skin perhaps because the intercellular “glue” is destroyed between keratinized cells like between peeling cells of the interfollicular epidermis.

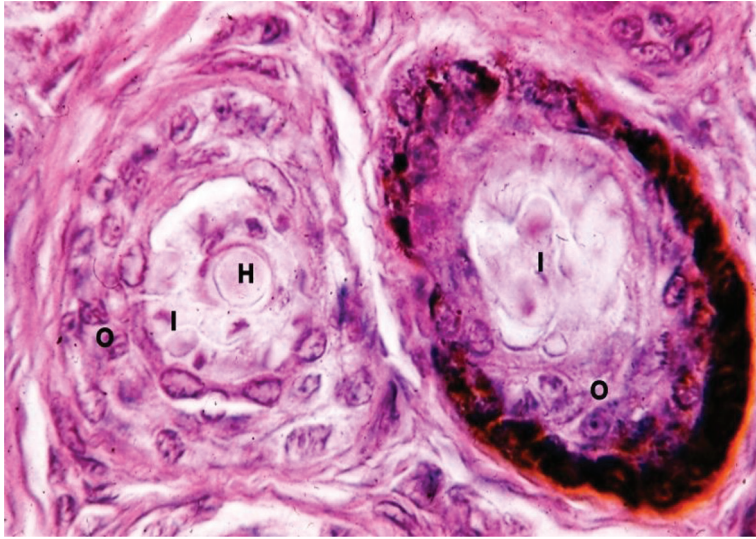
After some period of anchoring, the new matrix and bulb regenerate and the new hair starts to grow in this follicle. In such species as mice, one follicle in the early postnatal period can produce four generations of hairs all being kept anchored and allowing new hair to grow past them.

## 2. The hair follicle sites of resistance to hair pulling out of the skin

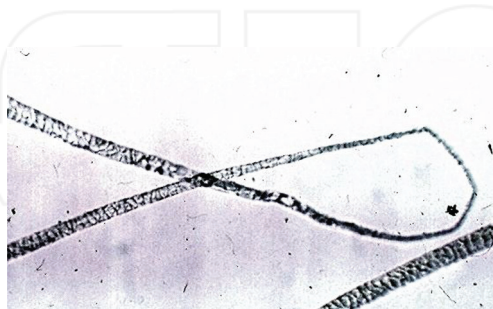So let us list the histological conditions necessary to keep the clearly visible hair shaft within the skin:

- (1) The hair shaft must not be too thin and short and rare (like on the cheek of a girl), or such underdeveloped hair most probably would be interpreted as hair loss (**Figure 8**).
- (2) There must not be extreme local thinnings of hair shafts caused by the short temporary action of mitostatic agents (stress—hydrocortisone, short time ionizing irradiation). Hairs can be easily broken in these thin sites and hair loss will take place (**Figure 9**).
- (3) The keratinization of the hair cortex cells must be perfect enough not to allow the hair to break easily especially after these cells leave the skin in the course of hair growth. The defects of the keratin can be caused by the parasitic organisms or genetic mutations or the lack of some nutrients.
- (4) When the hair grows, its fixation in the F is possible when the correct proportion of IS and hair cuticle layers are produced and their interaction takes place.
- (5) When the hair stops growing, its fixation in the skin for some time is possible only when the IS is not produced and cannot isolate the modified hair cortex cells of the brush-like proximal club-hair end from companion layer cells. Direct contact between the hair brush-like end and keratinized companion cells seems to be the main mechanism of telogen hair temporary fixation in the skin and postponing of the hair shedding.
- (6) Unlike the events in the “planned” catagen phase where the IS production is stopped and brush-like proximal hair shaft end is produced, the mitostatic agents do not stop IS formation, and nothing like brush-like proximal hair end is formed (merely thinning pointed end) (**Figure 10**). So the hair shedding is not postponed and is not fixed in the skin 8 days after any type of mitostatic action in the proper dose.
- (7) Relatively high proportion of hair F entered into telogen phase at any moment means that the hair will be neither long nor dense. Even postponed shedding will still in-

involve rather many hairs in shedding process at any moment and all these features will be interpreted as hair loss. So the hair loss can be partly decreased by the regulatory mechanisms prolonging anagen VI phase and lowering the proportion of F in the telogen phase.




**Figure 8.** Transverse histological sections of neighbor hair follicles of nude goat supposedly with nude mutation causing underdevelopment of hairs. The left follicle produced very thin hair (H) as well as rather developed hair root inner sheath (I). The right follicle produced only inner sheath (I) and no hair at all. O, well developed outer hair root sheaths. The right one includes some melanocytes producing melanin. Hematoxylin + eosin.



**Figure 9.** Hair dysplasia caused by the local fine-wool sheep skin X-irradiation by subepilation doze (300 sZv). The left and higher hair segment was formed before the irradiation. This segment is followed by one with some disturbance of normal structure (3 days after irradiation) and progressive thinning of the wool fiber. In the course of further growth, the restoration of original hair diameter took place (lower left hair segment).





**Figure 10.** Polarization microscopy picture of the lower end of the sheep hair which appeared as the result of local X-irradiation of the skin by epilation dose (500 sZv). No “club” or brush-like structures could be seen. White “shining” is caused by the capacity of the very dense keratin regular structure to turn the plane of light polarization between two crossed polaroids (dark background) of “NU” Carl Zeiss microscope.

## Abbreviations

F	Hair follicle
K	Keratins
KI	“Keratin-like” proteins
IS	Hair inner root sheath
OS	Hair outer root sheath

## Author details

Vsevolodov Eduard Borisovich

Address all correspondence to: [eduardvsevolodov@mail.ru](mailto:eduardvsevolodov@mail.ru)

Faculty of Biology and Biotechnology, Al-Farabi Kazakh National University, Almaty, Kazakhstan

## References

- [1] Vsevolodov, E.B., *Volosyanye follikuly (Hair Follicles)*, Alma-Ata: Nauka, 1979, pp. 1-190.
- [2] Rogers, G.E., Hair follicle differentiation and regulation, *Int. J. Dev. Biol.*, 2004, vol. 48, pp. 163-170.
- [3] Oh, J.W., et al., A guide to studying human hair follicle cycling in vivo, *J. Invest. Dermatol.*, 2015, pp. 1-124.

- [4] Vsevolodov, E.B., Golichenkov, V.A., and Latypov, I.F., Cellular dynamics of the outer layers of the hair follicle of fine-wool sheep during the phase of stable hair growth, *Russ. J. Dev Biol.*, 2014, vol. 45, no. 6, pp. 342-350, ISSN 1062-3604.
- [5] Hayflick, L., Aging under glass, *Exp. Gerontol.*, 1970, vol. 5, pp. 291-303.
- [6] Orwin, D.F.G., Cell differentiation in the lower outer sheath of the Romney wool follicle; a companion cell layer, *Aust. J. Biol. Sci.*, 1971, vol. 24, pp. 989-999.
- [7] Chapman, R.E., Cell migration in wool follicles of sheep, *J. Cell Sci.*, 1971, vol. 9, pp. 791-803.
- [8] Gemmel, R.T., and Chapman, R.E., Formation and breakdown of the inner root sheath and features of the pilary canal epithelium in the wool follicle, *J. Ultrastruct. Res.*, 1971, vol. 36, pp. 355-366.

INTECH

